

# American Journal of Sports Medicine

<http://ajs.sagepub.com>

---

## **Extracorporeal Shockwave for Chronic Patellar Tendinopathy**

Ching-Jen Wang, Jih-Yang Ko, Yi-Sheng Chan, Lin-Hsiu Weng and Shan-Lin Hsu  
*Am. J. Sports Med.* 2007; 35; 972 originally published online Feb 16, 2007;  
DOI: 10.1177/0363546506298109

The online version of this article can be found at:  
<http://ajs.sagepub.com/cgi/content/abstract/35/6/972>

---

Published by:

 SAGE Publications

<http://www.sagepublications.com>

On behalf of:



[American Orthopaedic Society for Sports Medicine](#)

**Additional services and information for *American Journal of Sports Medicine* can be found at:**

**Email Alerts:** <http://ajs.sagepub.com/cgi/alerts>

**Subscriptions:** <http://ajs.sagepub.com/subscriptions>

**Reprints:** <http://www.sagepub.com/journalsReprints.nav>

**Permissions:** <http://www.sagepub.com/journalsPermissions.nav>

**Citations** (this article cites 34 articles hosted on the  
SAGE Journals Online and HighWire Press platforms):  
<http://ajs.sagepub.com/cgi/content/abstract/35/6/972#BIBL>

# Extracorporeal Shockwave for Chronic Patellar Tendinopathy

Ching-Jen Wang,<sup>\*†</sup> MD, Jih-Yang Ko,<sup>†</sup> MD, Yi-Sheng Chan,<sup>‡</sup> MD,  
Lin-Hsiu Weng,<sup>†</sup> MD, and Shan-Lin Hsu,<sup>†</sup> MD

From the <sup>†</sup>Department of Orthopedic Surgery, Chang Gung Memorial Hospital, Chang Gung University College of Medicine, Kaohsiung, Taiwan, and the <sup>‡</sup>Department of Orthopedic Surgery, Chang Gung Memorial Hospital, Chang Gung University College of Medicine, Taoyuan, Taiwan

---

**Background:** Chronic patellar tendinopathy is an overuse syndrome with pathologic changes similar to tendinopathies of the shoulder, elbow, and heel. Extracorporeal shockwave was shown effective in many tendinopathies.

**Hypothesis:** Extracorporeal shockwave therapy may be more effective than conservative treatment for chronic patellar tendinopathy.

**Study Design:** Randomized controlled clinical trial; Level of evidence, 2.

**Methods:** This study consisted of 27 patients (30 knees) in the study group and 23 patients (24 knees) in the control group. In the study group, patients were treated with 1500 impulses of extracorporeal shockwave at 14 KV (equivalent to 0.18 mJ/mm<sup>2</sup> energy flux density) to the affected knee at a single session. Patients in the control group were treated with conservative treatments including nonsteroidal anti-inflammatory drugs, physiotherapy, exercise program, and the use of a knee strap. The evaluation parameters included pain score, Victorian Institute of Sports Assessment score, and ultrasonographic examination at 1, 3, 6, and 12 months and then once a year.

**Results:** At the 2- to 3-year follow-up, the overall results for the study group were 43% excellent, 47% good, 10% fair, and none poor. For the control group, the results were none excellent, 50% good, 25% fair, and 25% poor. The mean Victorian Institute of Sports Assessment scores were 42.57 ± 10.22 and 39.25 ± 10.85, respectively, before treatment ( $P = .129$ ) and 92.0 ± 10.17 and 41.04 ± 10.96, respectively, after treatment ( $P < .001$ ). Satisfactory results were observed in 90% of the study group versus 50% of the control group ( $P < .001$ ). Recurrence of symptoms occurred in 13% of the study group and 50% of the control group ( $P = .014$ ). Ultrasonographic examination showed a significant increase in the vascularity of the patellar tendon and a trend of reduction in the patellar tendon thickness after shockwave treatment compared with conservative treatments. However, no significant difference in the appearance, arrangement, and homogeneity of tendon fibers was noted between the 2 groups. There were no systemic or local complications or device-related problems.

**Conclusion:** Extracorporeal shockwave therapy appeared to be more effective and safer than traditional conservative treatments in the management of patients with chronic patellar tendinopathy.

**Keywords:** patellar; tendinopathy; chronic; shockwave; conservative treatment

---

Patellar tendinopathy is a common orthopaedic problem characterized by pain and tenderness just below or, less commonly, above the patella.<sup>1,6,34</sup> With an increase in frequency, duration, and intensity of quadriceps contraction

in activities that require repetitive knee extension and flexion, the patellar tendon can develop microtears at the attachment site to the inferior pole of the patella. The pathologic changes seen in this condition are similar to those of other overuse injuries, including lateral epicondylitis (tennis elbow) or plantar fasciitis (painful heel syndrome).<sup>8,11,12</sup> Conservative treatments have been proposed as the initial choice for patellar tendinopathy, including cessation of the offending activity until symptoms subside; stretching and strengthening exercises for the quadriceps, hamstrings, and patellar tendon; applying heat before and ice after exercise; the use of nonsteroidal anti-inflammatory drugs (NSAIDs); and the use of a patellar strap to reduce

---

\*Address correspondence to Ching-Jen Wang, MD, Department of Orthopedic Surgery, Chang Gung Memorial Hospital, Chang Gung University College of Medicine, 123 Ta-Pei Road, Niao-Sung Hsiang, Kaohsiung, Taiwan 833 (e-mail: w281211@adm.cgmh.org.tw).

No potential conflict of interest declared.

stress on the patellar tendon. The results of conservative treatment have been irregular and inconsistent, and the symptoms frequently recur.<sup>1,4</sup> Surgery has been suggested as the alternative method of treatment for severe cases that do not respond to conservative treatments. However, the results of surgery are unpredictable, and it is associated with surgical risks and complications.<sup>5,7,19</sup>

Recently, extracorporeal shockwave has been shown effective in alleviating pain and restoring function attributable to tendinopathies of the shoulder, elbow, and heel and for promoting bone healing.<sup>16,20,21,23-28,31,33</sup> The clinical results showed approximately 90% good or excellent results with 5% to 7% recurrence rate in shoulder, elbow, and heel and 80% success in nonunions of long bone fractures.<sup>3,13,26,27,31,33</sup> In animal experiments, some studies reported that shockwave therapy significantly decreased the nonmyelinated sensory fibers and loss of calcitonin gene-related peptide and reduction in substance P release.<sup>15,18</sup> Others demonstrated that shockwave stimulates the ingrowth of neovascularization at the tendon-bone junction and in bone.<sup>29,30,32</sup> Because the pathologic changes of patellar tendinopathy are similar to other overuse injuries, including tennis elbow and plantar fasciitis,<sup>11,12</sup> we hypothesized that shockwave treatment may produce similar results in patients with patellar tendinopathy. The purpose of this study was to evaluate the efficacy and safety of shockwave treatment and to compare the result with that of conservative treatment for patients with chronic patellar tendinopathy.

## PATIENTS AND METHODS

Chronic patellar tendinopathy is defined as recurrent pain and tenderness attributable to degenerative changes of the patellar tendon for at least 6 months. The inclusion and exclusion patient selection criteria are shown below.

### Inclusion Criteria

1. Patients with a diagnosis of chronic patellar tendinopathy established by medical history and physical examination
2. Patients who experienced pain of 5.0 or greater on a 0-to-10 visual analog scale while walking up and down stairs
3. Patients who understood and complied with the nature of the study participation
4. Patients who were 21 years and older and skeletally matured
5. Patients who were physically and mentally competent to sign the informed consent form
6. Patients who were in good general health

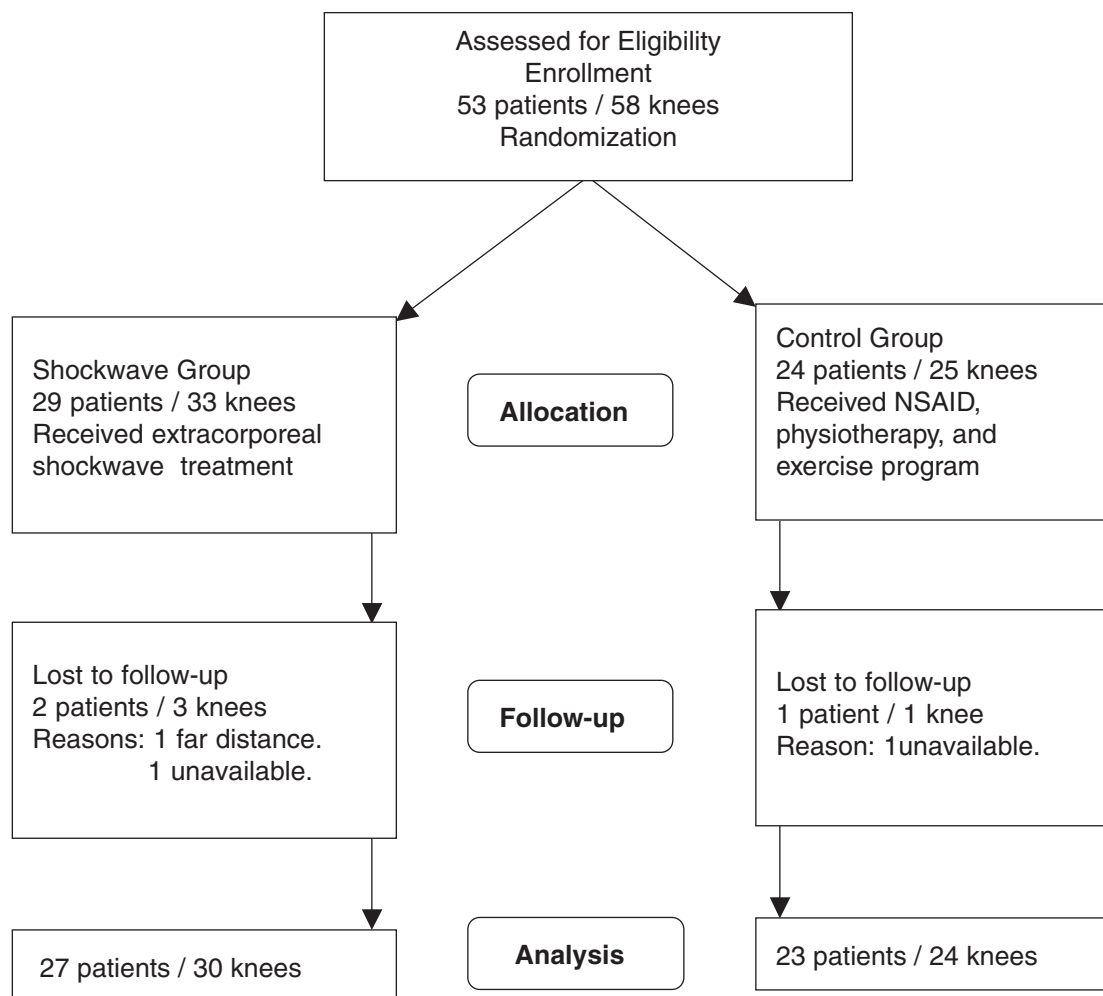
### Exclusion Criteria

1. Patients who received a cortisone injection within 6 weeks
2. Patients on immunosuppressant agents and/or corticosteroid within 6 months

3. Patients with diabetes mellitus, occlusive vascular disease, collagen disease, osteoarthritis or rheumatoid arthritis, coagulopathy, or infection
4. Patients with radiographic fractures around the knee
5. Patients with cardiac arrhythmia or cardiac pacemaker
6. Patients who were pregnant

The Institutional Review Board of our hospital approved this study. All patients were required to sign an informed consent form before study participation. Between October 2001 and May 2005, 53 patients with 58 injured knees were initially assessed for eligibility and enrolled in the study. Patients were randomly divided into 2 groups by assigning patients with an odd medical record number to the study group and patients with an even number to the control group. During the course of treatment, 3 patients (4 knees) were lost to follow-up and were excluded from the study. The remaining 50 patients (54 knees) completed the analyses in this study. The flow diagram of patient recruitment is shown in Figure 1. The study group consisted of 27 patients (30 knees) and the control group of 23 patients (24 knees). Three patients in the study group and 1 patient in the control group were treated for bilateral knee injuries. Patellar tendinopathy involved the proximal end of the patellar tendon in all knees. The average duration of the disease was  $16.2 \pm 17.2$  months (range, 6-64 months) versus  $11.3 \pm 10.9$  months (range, 6-46 months), and the average follow-up was  $32.7 \pm 10.8$  months (range, 10-53 months) versus  $28.6 \pm 9.8$  months (range, 10-48 months) for the study group and the control group, respectively. Some patients were initially treated at another institution and subsequently referred to our hospital, whereas others came to our outpatient clinic at the onset of symptoms. The duration of the disease included the time while patients were treated elsewhere, whereas the length of follow-up only included the time of treatment at our hospital. There were 29 recreational athletes including 15 in the study group and 14 in the control group. Their sports and numbers of participants were 9 basketball, 2 jogging, 2 handball, 1 weight lifting, and 1 wrestling for the study group, and 8 basketball, 2 jogging, 2 handball, 1 weight lifting, and 1 wrestling for the control group. The patient demographic characteristics are summarized in Table 1.

Patients in the study group received shockwave treatment as outpatients with no local or regional anesthesia. The source of shockwave was from an OssaTron (High Medical Technology, Kreuzlingen, Switzerland). Each knee was treated with 1500 impulses of shockwave at 14 KV (equivalent to  $0.18 \text{ mJ/mm}^2$  energy flux density) in a single session. The dosage was chosen based on our previous experience in shockwave application for other tendinopathies.<sup>3,13,26,28,31,33</sup> The point of maximal tenderness was elicited by palpation, and the location of the lesion was focused with the laser control guide of the device. The depth of treatment was estimated clinically and confirmed with an ultrasound guide. Surgical lubricant was applied to the skin in contact with the shockwave tube. Treatment began with slow frequency at 1 impulse of shock per second and gradually increased to 2 shocks per second as the patient could tolerate the procedure.



**Figure 1.** The flow diagram showing patient selection. NSAID, nonsteroidal anti-inflammatory drug.

Immediately after treatment, the area was inspected for swelling, ecchymosis, and hematoma. Postoperative management included ice pack to the treatment site and a prescription of nonnarcotic analgesic, such as acetaminophen. Patients were allowed to resume light activity; however, heavy activities including sports were not permitted for 4 to 6 weeks.

Three patients (4 knees) also received a second treatment because of either inadequate response or recurrent symptoms 4 to 6 weeks after the first treatment. Inadequate response was defined when the patient showed less than 50% improvement and experienced pain at 5.0 or greater on a 0-to-10 visual analog scale (VAS) on stairs and palpation. The dosage of the second shockwave application was the same as the first treatment.

Patients in the control group were treated with conservative treatments including NSAIDs, physiotherapy, an exercise program, the use of a knee strap, and modification of activity levels. Physiotherapy modalities included hot and cold packs, phonophoresis, and friction massage. The exercise program included a primarily eccentric stretching exercise of the patellar tendon and strengthening exercises of the quadriceps and hamstrings. Most patients started

out with the administration of NSAIDs. A Cox-2 specific inhibitor (celecoxib) was prescribed to patients who developed allergic reaction or gastrointestinal toxicity to NSAIDs. Patients were then treated with multiple modalities when they failed to respond adequately to treatment with a single modality. Nearly all patients eventually received multiple modalities during the course of treatment. None received local cortisone injection.

#### Evaluation Parameters

The follow-up examinations were scheduled at 1, 3, 6, and 12 months and then once a year. Evaluations were carried out by telephone interview in 9 patients (10 knees), including 4 patients (4 knees) in the study group and 5 patients (6 knees) in the control group. The remaining evaluations were performed in person by an independent examiner blinded to the nature of the study protocol. The evaluation parameters included pain score, Victorian Institute of Sport Assessment (VISA)<sup>4,12</sup> score for symptoms and function of the knee, and ultrasonographic examination. The intensity of pain was measured on a visual analog scale from 0 to 10, with 0 for no pain and 10 for severe pain on palpation and on

TABLE 1  
Patient Demographic Characteristics<sup>a</sup>

	Study Group	Control Group	P Value
Number of patients	27	23	
Number of knees	30	24	
Average age, y	29.4 ± 10.5 (16-47)	30.2 ± 10.4 (16-46)	.395
Gender, male/female	14/13	13/10	
Side, right/left	9/21	5/19	
Bilateral knees	3	1	
Average duration of disease, mo	16.2 ± 17.2 (6-64)	11.3 ± 10.9 (6-46)	.09
Average follow-up, mo	32.7 ± 10.8 (10-53)	28.6 ± 9.8 (10-48)	.07
Sports participation			
Basketball	9	8	
Jogging	2	2	
Weight lifting	1	1	
Wrestling	1	1	

<sup>a</sup>Ranges are in parentheses.

walking upstairs and downstairs, and the consumption of pain medication. The symptoms and function of the knee were graded with a 100-point VISA scale.<sup>4,12</sup> The functional improvement of the knee was subjectively assessed by the patients and measured by the performance of activities of daily living, including sports. The result was considered satisfactory if patients had 75% or more improvement in pain with 4.0 or less on a VAS scale while walking up and down stairs and did not take any pain medication. The clinical outcomes were graded excellent, good, fair, or poor. An excellent result was defined as the knee having no pain in all activities including sports. A good result was defined as the knee having 75% or more improvement and mild pain with a VAS less than 4 in all activities including sports. A fair result was defined as the knee having 50% or more improvement and moderate pain with a VAS less than 4 in any activities including sports. A poor result was defined as the knee having less than 50% improvement and significant pain with a VAS greater than 4 in any activities including sports.

Ultrasonographic examinations of the proximal patellar tendon were performed before and after treatment. High-resolution sonography was performed by using a Sequoia 512 scanner (Acuson, Mountain View, Calif) with a linear 8L5 transducer with the setting at 8 MHz. Routine color Doppler study was also performed to evaluate the vascularity of the patellar tendon. A radiologist blinded to the study protocol interpreted the results of ultrasonographic study. Ultrasound studies were used to evaluate the dimension and thickness of the proximal patellar tendon; the presence of edema or swelling within the tendon; the appearance, arrangement, and homogeneity of tendon fibers; and the vascularity of the patellar tendon.

### Statistical Analyses

A power analysis revealed that a sample size of 23 would be required to establish the statistical significance with  $\alpha = .05$

TABLE 2  
Pain Score, VISA Score, and Functional Improvement  
Before and After Treatment<sup>a</sup>

	Study Group (n = 30)	Control Group (n = 24)	P Value (2)
Pain scores (VAS)			
Before treatment			
Mean ± SD	6.00 ± 1.74	5.38 ± 0.92	.120
(Range)	(5-9)	(5-7)	
After treatment			
Mean ± SD	0.59 ± 1.01	4.72 ± 1.35	<.001
(Range)	(0-3)	(2-7)	
P value (1)	<.001	.450	
VISA scores			
Before treatment			
Mean ± SD	42.57 ± 10.22	39.25 ± 10.85	.129
(Range)	(24-67)	(21-63)	
After treatment			
Mean ± SD	92.0 ± 10.17	41.04 ± 10.96	<.001
(Range)	(63-100)	(23-65)	
P value (1)	<.001	.286	
Range of knee motion, deg			
Before treatment			
Mean ± SD	139 ± 2.5	134 ± 6.1	.139
(Range)	(125-140)	(125-140)	
After treatment			
Mean ± SD	150 ± 0.00	136 ± 6.6	.001
(Range)	(150-150)	(130-145)	
P value (1)	<.001	.109	
Functional improvement after treatment, % <sup>b</sup>			
Mean ± SD	84.8 ± 20.5	56.7 ± 26.7	<.001
(Range)	(30-100)	(10-80)	

<sup>a</sup>VISA, Victorian Institute of Sports Assessment score; VAS, visual analog scale from 0 to 10; P value (1), Comparison of data before and after treatment of the same group; P value (2), Comparison of data between the study group and the control group.

<sup>b</sup>The percentage of functional improvement of the knee was based on the overall subjective assessment by comparing with the baseline status before treatment.

and power = 0.8, with calculation based on the outcomes of extracorporeal shockwave and conservative treatment for chronic patellar tendinopathy in this study. The data before and after treatment within the same group were compared statistically using a paired *t* test, the data between the study and control groups were compared with the Mann-Whitney test, and the overall results and the changes in the vascularity on ultrasonography between the 2 groups were compared with the  $\chi^2$  test with statistical significance at  $P < .05$ .

### RESULTS

The results of the pain score, VISA score, range of knee motion, and functional improvement are summarized in Table 2. Significant improvements in pain score, VISA score, and knee motion after treatment were noted in the study group ( $P < .001$ ). However, the improvements in the control group were statistically not significant ( $P > .05$ ).



TABLE 3  
Overall Clinical Outcomes of the Study  
and Control Groups<sup>a</sup>

	Study Group (n = 30)	Control Group (n = 24)
Excellent	43 (13/30)	0
Good	47 (14/30)	50 (12/24)
Fair	10 (3/30)	25 (6/24)
Poor	0	25 (6/24)
Recurrence	13 (4/30)	50 (12/24)
<i>P</i> value	<.001	

<sup>a</sup>Values are % (n). Excellent, No pain in all activities of daily living including sports; good, >75% improvement and had mild pain with visual analog scale less than 4 in any activities including sports; fair, >50% improvement and had moderate pain with visual analog scale less than 4 in any activities including sports; poor, <50% improvement and had significant pain with visual analog scale greater than 4 in any activities including sports. *P* value was calculated based on  $\chi^2$  test.

The differences in pain score, VISA score, and knee motion between the 2 groups were statistically not significant ( $P > .05$ ) before treatment. However, the differences became statistically significant after treatment, favoring the study group ( $P < .05$ ). The subjective assessment for functional improvement of the knee after treatment was 84.8% for the study group versus 56.7% for the control group ( $P < .001$ ).

The overall clinical outcomes are summarized in Table 3. The overall results were excellent in 43%, good in 47%, fair in 10%, and poor in none for the study group, and excellent in 0%, good in 50%, fair in 25%, and poor in 25% for the control group ( $P < .001$ ). Satisfactory results were observed in 90% of the study group versus 50% of the control group ( $P < .001$ ). Recurrent symptoms were noted in 13% (4 of 30) of the study group and 50% (12 of 24) of the control group ( $P = .014$ ). Three patients (4 knees) in the study group had a second shockwave treatment for either recurrent symptoms or inadequate response from the first treatment, and the results were excellent in 1, good in 1, and fair in 2.

For athletic participation, 10 of 15 patients in the study group were able to return to the same level of sports activities including basketball in 5, jogging in 2, handball in 1, weight lifting in 1, and wrestling in 1, and the other 5 patients were able to return at lower levels including basketball in 4 and handball in 1. For the control group, 14 of 14 athletic patients were able to return to sports activities at lower levels and none at the same level of sports activities before the treatment.

The results of ultrasonographic examination of the patellar tendon are summarized in Table 4. There was a 6% decrease in the proximal patellar tendon thickness after shockwave treatment versus a 10% increase in the control group. However, the difference in the changes of patellar tendon thickness between the 2 groups was statistically not significant after treatment ( $P = .219$ ). In the study group, the vascularity of the patellar tendon showed an increase in 7 and was unchanged in 23 before treatment versus an increase in 15 and no change in 15 after treatment ( $P = .032$ ). In the control group, the vascularity

TABLE 4  
Results of Ultrasonographic Examination<sup>a</sup>

	Study Group (n = 30)	Control Group (n = 24)	<i>P</i> Value (2)
Patellar tendon thickness			
Before treatment			
Mean $\pm$ SD	0.51 $\pm$ 0.17	0.46 $\pm$ 0.16	.177
(Range)	(0.23 – 0.86)	(0.23 – 0.86)	
After treatment			
Mean $\pm$ SD	0.48 $\pm$ 0.11	0.51 $\pm$ 0.12	.219
(Range)	(0.29 – 0.60)	(0.38 – 0.78)	
Changes (%)	–6	10	
<i>P</i> value (1)	.295	.154	
Vascularity			
Before treatment			
Increased	7	4	.546
Unchanged	23	20	
After treatment			
Increased	15	5	.027
Unchanged	15	19	
<i>P</i> value (1)	.032	.712	

<sup>a</sup>The data of patellar tendon thickness were obtained from the proximal end of the patellar tendon near the insertion to the inferior pole of the patella. *P* value (1), comparison of data before and after treatment within the same group; *P* value (2), comparison of data between the study group and the control group.

showed an increase in 4 and no change in 20 before treatment versus an increase in 5 and no change in 19 after treatment ( $P = .712$ ). The difference in the vascularity of the patellar tendon between the 2 groups was statistically not significant before treatment ( $P = .546$ ); however, the difference was statistically significant after treatment ( $P = .027$ ). There was no significant difference in the appearance, arrangement, and homogeneity of the tendon fibers between the 2 groups.

### Complications

One patient from the study group developed transient numbness and hypoesthesia around the anteromedial aspect of the knee that resolved spontaneously with ice pack and observation. There were no systemic or local complications directly or indirectly related to the use of the device. There was no device-related problem.

### DISCUSSION

Patellar tendinopathy is defined as a degenerative process of the patellar tendon of unknown origin. Chronic patellar tendinopathy is an overuse syndrome manifested with pain and tenderness attributable to mucoid and chondroid degeneration, formation of plump tenocytes, increased fibroblastic and myofibroblastic cells, and absent inflammatory cells.<sup>11,12,19</sup> Some studies reported that a chronic painful patellar tendon exhibits increased occurrence of sprouting nonvascular sensory, substance P–positive nerve fibers, and decreased occurrence of vascular sympathetic nerve fibers and suggested that the altered sensory-sympathetic innervation may play a role

in the pathogenesis of tendinopathy.<sup>14</sup> Conservative treatments including modification of activity; stretching and strengthening exercises for the quadriceps, hamstrings, and patellar tendon; physiotherapy with heat and cold compressions and transfriction massage; and the use of a patellar strap to reduce stress on the patellar tendon are recommended as the initial treatments of choice for chronic patellar tendinopathy.<sup>1,5,6</sup> The results of conservative treatment were inconsistent, and pain and tenderness frequently recurred.<sup>1,5</sup> Surgery is indicated for cases with failure to conservative treatments.<sup>7,8</sup> However, the results of surgical treatment are unpredictable and inconsistent.<sup>4,5,7,19</sup> Some studies reported that sclerosing injections with polidocanol resulted in significant improvement in knee function and reduced pain in patients with patellar tendinopathy.<sup>10</sup> The results of the current study showed that extracorporeal shockwave treatment produced superior results to traditional conservative treatments for patients with chronic patellar tendinitis. The recurrent rate was lower, and the complications were negligible.

Currently, Food and Drug Administration–approved shockwave devices included Sanuwave OssaTron, Dornier Epos, Siemens Sonocur, and Medscape Orthospec. High- and low-energy shockwave devices are manufactured by different sources of shockwave generators including electrohydraulic, electromagnetic, and piezoelectric. In clinical application, multiple treatments are required with low-energy devices, whereas single treatment is recommended with high-energy machines. In this study, the high-energy OssaTron (High Medical Technology) orthotripter was used, and patients received a single session of treatment. The majority of the published papers showed positive effects of high-energy shockwave in various tendinopathies of the shoulder, elbow, knee, and heel.<sup>3,13,16,20,21,23-25,31,33</sup> Only a few studies reported less favorable results comparable with placebo effect.<sup>2,9</sup> The discrepancy was attributed to bias in patient selection, the use of low-dose shockwave in the control group, the use of different low-energy devices, and a short follow-up of 12 to 15 weeks.

Many studies reported the cumulative effects of shockwave in the treatment of tendinopathies of the shoulder, elbow, and heel.<sup>3,13,26,28,31,33</sup> In this study, 3 patients (4 knees) also received a second treatment, and the results were 1 excellent, 1 good, and 2 fair. It appeared that shockwave treatment showed a cumulative effect in chronic patellar tendinopathy similar to other tendinopathies. Some authors reported that repetitive low-energy shockwave application without local anesthesia is more effective than repetitive low-energy shockwave application with local anesthesia in the treatment of chronic plantar fasciitis.<sup>22</sup> In this study, no local or regional anesthesia was given, and all patients tolerated the procedure well without adverse complications.

The mechanism of shockwave remains unknown. Some studies speculated that shockwave relieves pain caused by tendinopathy through hyperstimulation analgesia by increasing the painful level of stimulation.<sup>17</sup> Ohtori et al<sup>18</sup> demonstrated that low-energy shockwave produced morphologic changes in cutaneous nerve fibers with significant decreases in the number of sensory fibers and loss of calcitonin

gene-related peptide after shockwave application. Maier et al<sup>15</sup> showed that high-energy extracorporeal shockwave to the distal rabbit femur resulted in a reduced concentration of substance P in the femoral periosteum 6 weeks after shockwave application. These studies indicated that shockwave may selectively lead to dysfunction of peripheral sensory unmyelinated nerve fibers without affecting large myelinated nerve fibers responsible for motor function. Other studies in animal experiments demonstrated that shockwave stimulated the ingrowth of neovascularization associated with increased expressions of angiogenic growth factors including endothelial nitric oxide synthase, vessel endothelial growth factor, and proliferating cell nuclear antigen.<sup>30,32</sup> Neovascularization may play a role in the improvement of blood supply leading to tissue regeneration in tendinopathy. Chronic patellar tendinopathy manifested as mucoid and chondroid degeneration of the tendon fibers, increased fibroblastic and myofibroblastic cells, and altered sensory-sympathetic innervation.<sup>11,12,14,19</sup> In this study, a significant increase in the vascularity of the patellar tendon was noted after shockwave treatment. It appeared that shockwave treatment resulted in an increase in microscopic neovascularity in animal experiment as well as an increase in macroscopic vascularity of the patellar tendon on ultrasonographic study. It is reasonable to believe that shockwave relieved pain by hyperstimulation analgesia, improvement in blood supply, and promotion of tissue regeneration in chronic patellar tendinopathy.

There are limitations in this study. The number of patients was small even though they met the power requirement. The length of follow-up was relatively short. The functional improvement of the knee was assessed subjectively on the performance of daily activities including sports participation. The grading method on the clinical outcome of excellent, good, fair, and poor in this study is not validated. In addition, the method of patient randomization by medical record number potentially compromised the concealment of patient assignment.

## CONCLUSION

Extracorporeal shockwave treatment appeared to be more effective and safer than traditional conservative treatment in the management of patients with chronic patellar tendinopathy.

## ACKNOWLEDGMENT

Funds were received in total or partial support for the research or clinical study presented in this article. The funding source was from Chang Gung Research Fund (CMRP 8015) and National Health Research Institute (NHRI-EX95-9423EP). No benefits in any form have been received or will be received from a commercial party related directly or indirectly to the subject of this article.

## REFERENCES

1. Blazina ME, Kerlan RK, Jobe FW, Carter VS, Carlson GJ. Jumper's knee. *Clin North Am.* 1973;4:665-678.

2. Buchbinder R, Ptasznik R, Gordon J, Buchanan J, Prabakaran V, Forbes A. Ultrasound-guided extracorporeal shock wave therapy for plantar fasciitis. A randomized control trial. *JAMA*. 2002;288:1364-1372.
3. Chen HS, Chen LM, Huang TW. Treatment of painful heel syndrome with shock wave. *Clin Orthop Relat Res*. 2001;387:41-46.
4. Coleman BD, Khan KM, Maffulli N, Cook JL, Wark JD. Studies of surgical outcome after patellar tendinopathy: clinical significance of methodological deficiencies and guidelines for future studies. Victorian Institute of Sport Tendon Study Group. *Scand J Med Sci Sports*. 2000;10:2-11.
5. Colosimo AJ, Bassett FH. Jumper's knee: diagnosis and treatment. *Orthop Rev*. 1990;19:139-149.
6. Eifert-Mangine M, Brewster C, Wong M, Shields C Jr, Noyes FR. Patellar tendinitis in the recreational athlete. *Orthopedics*. 1992;15:1359-1367.
7. Fritschy D, Wallensten R. Surgical treatment of patellar tendinitis. *Knee Surg Sports Traumatol Arthrosc*. 1993;1:131-133.
8. Griffiths GP, Selesnick FH. Operative treatment and arthroscopic findings in chronic patellar tendonitis. *Arthroscopy*. 1998;14:836-839.
9. Haake M, Buch M, Schoellner C, et al. Extracorporeal shock wave therapy for plantar fasciitis: randomized controlled multicentre trial. *Br Med J*. 2003;327:75-79.
10. Hoksrud A, Öhberg L, Alfredson H, Bahr R. Ultrasound-guided sclerosis of neovessels in painful chronic patellar tendinopathy: a randomized controlled trial. *Am J Sports Med*. 2006;34:1738-1746.
11. Khan KM, Cook JL, Bonar F, Harcourt P, Astrom M. Histopathology of common tendinopathies. Update and implications for clinical management. *Sports Med*. 1999;27:393-408.
12. Khan KM, Maffulli N, Coleman BD, Cook JL, Taunton JE. Patellar tendinopathy: some aspects of basic science and clinical management. *Br J Sports Med*. 1998;32:346-355.
13. Ko JY, Chen HS, Chen LM. Treatment of lateral epicondylitis of the elbow with shock waves. *Clin Orthop Relat Res*. 2001;387:60-67.
14. Lian Ø, Dahl J, Ackermann P, Frihagen F, Engegretsen L, Bahr R. Pronociceptive and antinociceptive neuromediators in patellar tendinopathy. *Am J Sports Med*. 2006;34:1801-1808.
15. Maier M, Averbeck B, Milz S, Refior HJ, Schmitz C. Substance P and prostaglandin E2 release after shockwave application to the rabbit femur. *Clin Orthop Relat Res*. 2003;406:237-245.
16. Maier M, Steinborn M, Schmitz C, et al. Extracorporeal shock wave application for chronic plantar fasciitis associated with heel spurs: prediction of outcome by magnetic resonance imaging. *J Rheumatology*. 2000;27:2455-2462.
17. Ogden JA, Alvarez RG, Levitt R, Marlow M. Shock wave therapy (lithotripsy) in musculoskeletal disorders. *Clin Orthop Relat Res*. 2001;387:22-40.
18. Ohtori S, Inoue G, Mannoji C, et al. Shockwave application to rat skin induces degeneration and reinnervation of sensory nerve fibers. *Neurosci Lett*. 2001;315:57-60.
19. Popp JE, Yu JS, Kaeding CC. Recalcitrant patellar tendinitis: magnetic resonance imaging, histological evaluation, and surgical treatment. *Am J Sports Med*. 1997;25:218-222.
20. Rompe JD, Joellner J, Nafe B. Shock wave therapy versus conventional surgery in the treatment of calcifying tendonitis of the shoulder. *Clin Orthop Relat Res*. 2001;387:72-82.
21. Rompe JD, Kirkpatrick CJ, Kullmer K, Schwitalle M, Kricshek O. Dose-related effects of shock waves on rabbit tendo Achillis. A sonographic and histological study. *J Bone Joint Surg Br*. 1998;80:546-552.
22. Rompe JD, Meurer A, Nafe B, Hofmann A, Gerdesmeyer L. Repetitive low-energy shock wave application without local anesthesia is more effective than repetitive low-energy shock wave application with local anesthesia in the treatment of chronic plantar fasciitis. *J Orthop Res*. 2005;23:931-941.
23. Schaden W, Fischer A, Sailer A. Extracorporeal shock wave therapy for nonunion or delayed osseous union. *Clin Orthop Relat Res*. 2001;387:90-94.
24. Speed CA, Nichols D, Richards S, et al. Extracorporeal shock wave therapy for lateral epicondylitis—a double blind randomized control trial. *J Orthop Res*. 2002;20:895-898.
25. Spindler A, Berman A, Lucero E, Braier M. Extracorporeal shock wave treatment for chronic calcific tendonitis of the shoulder. *J Rheumatol*. 1998;25:1161-1163.
26. Wang CJ, Chen HS. Shock wave therapy for patients with lateral epicondylitis of the elbow: a one- to two-year follow-up study. *Am J Sports Med*. 2002;30:422-425.
27. Wang CJ, Chen HS, Chen CE, Yang KD. Treatment of nonunions of long bone fractures with shock waves. *Clin Orthop Relat Res*. 2001;387:95-101.
28. Wang CJ, Chen HS, Chen WS, Chen LM. Treatment of painful heel using extracorporeal shock wave. *J Formosa Med Assoc*. 2000;99:580-583.
29. Wang CJ, Huang HY, Chen HS, Pai CH, Yang KD. Effect of shock wave therapy on acute fractures of the tibia. A study in a dog model. *Clin Orthop Relat Res*. 2001;387:112-118.
30. Wang CJ, Huang SY, Pai CH. Shock wave enhanced neovascularization at the tendon-bone junction. A study in a dog model. *J Foot Ankle Surg*. 2002;41:16-22.
31. Wang CJ, Ko JY, Chen HS. Treatment of calcifying tendinitis of the shoulder with shock wave therapy. *Clin Orthop Relat Res*. 2001;387:83-89.
32. Wang CJ, Wang FS, Yang KD, et al. Shock wave therapy induces neovascularization at the tendon-bone junction. A study in rabbits. *J Orthop Res*. 2003;21:984-989.
33. Wang CJ, Yang KD, Chen HS, Wang FS, Wang JW. Shock wave therapy for calcifying tendonitis of the shoulder. *Am J Sports Med*. 2003;31:425-430.
34. Young D. Patellar tendonitis. *Aust Fam Physician*. 1989;18:1021.